

Argon green-Nd: YAG dual laser posterior hyaloidotomy: An innovative approach toward treatment of premacular hemorrhage

Abstract

Background: Neodymium: YAG (Nd: YAG) laser and argon laser has been used to treat premacular hemorrhage either alone or rarely in combination. **Materials and Methods:** We describe a new technique of treating premacular hemorrhage by performing hyaloidotomy using a combination of argon green-Nd: YAG laser. We utilized subthreshold energy levels of Nd: YAG laser of 2.0 mj as compared to the normal recommendation of 3.6-50 mj. **Results and Conclusions:** This technique is easy, effective, and safe to manage premacular hemorrhage. The principle behind this combined laser treatment was to make the internal limiting membrane (ILM) taut by initial exposure to argon green laser, which allowed us to employ the subthreshold energy levels of Nd: YAG laser. We would like to assess the role of this combined treatment modality in comparison to other modalities, including solitary laser therapy in the management of premacular hemorrhage by performing a prospective, randomized long-term study.

Key words:

Argon green laser hyaloidotomy, Neodymium-doped yttrium aluminum garnet laser hyaloidotomy, premacular hemorrhage, valsalva retinopathy

Introduction

Premacular hemorrhage is associated with a variety of condition such as valsalva retinopathy, proliferative diabetic retinopathy (PDR), macroaneurysms, retinal venous occlusions, blood dyscrasias, and may be idiopathic.^[1] Spontaneous absorption of the hemorrhage may take several weeks to months to resolve.^[1] The therapeutic options include observation, vitrectomy, or laser posterior hyaloidotomy (either Neodymium: YAG (Nd: YAG) laser or argon laser).^[1-3] We hereby report a case of premacular hemorrhage for which we have employed a combination of argon laser and Nd: YAG laser for posterior hyaloidotomy.


Materials and Methods

A 25-year-old female of Asian origin in her 8th month of pregnancy presented with complaint of sudden onset of painless diminution of vision in the right eye since 4 days.

Her previous medical history was unremarkable. Her best corrected visual acuity (BCVA) was finger counting (FC) 1 meter in OD and 20/20 in OS. Examination of the left eye was normal. Slit lamp biomicroscopy of the right eye revealed a normal anterior segment. Her intraocular pressure was 16 mmHg in both eyes with applanation tonometry. Her right eye fundus examination showed presence of a boat-shaped fresh premacular hemorrhage [Figure 1]. No other vitro-retinal pathology was evident.

Her blood pressure, complete blood counts, blood sugars, and coagulation profile were within normal limits. She was diagnosed as a case of right-sided premacular hemorrhage secondary to valsalva retinopathy in pregnancy. Since the vision was grossly affected, a decision was taken to drain the hemorrhage by laser hyaloidotomy.

Three spots of argon green laser were applied at the inferior portion of the anterior surface of the premacular hemorrhage

Access this article online	
Website: www.cysonline.org	Quick Response Code 
DOI: 10.4103/2229-5186.115559	

Ashish Sharma, Jay U. Sheth

Department of Retina, Lotus Eye Care Hospital,
Coimbatore, Tamil Nadu, India

Address for correspondence:

Dr. Ashish Sharma,
Retina and Research, Lotus Eye Care Hospital,
Coimbatore - 641 041, Tamil Nadu, India.
E-mail: drashish79@hotmail.com

with a spot size 100 μm , exposure duration of 0.10 s, and power of 200 mW. This mild photocoagulation led to the creation of folds of the internal limiting membrane (ILM) over hemorrhage [Figure 2]. Once the ILM folds were prominent, we subsequently created a defect over its inferior part with three spots of Nd: YAG laser of 2.0 mJ energy. Blood started draining almost immediately once the defect was made [Figures 3 and 4]. The patient was discharged and advised to use two pillows, while sleeping and minimize physical stress. At the subsequent follow-up visit at 1 week, the premacular hemorrhage was completely cleared out and the BCVA improved to 20/20 in OD. Minimal vitreous turbidity was noted.

Results and Discussion

A patient with a premacular hemorrhage presents with sudden profound loss of vision. Spontaneous reabsorption of the hemorrhage may take several weeks

to months.^[1] During this period, permanent visual loss may occur secondary to proliferative vitreoretinopathy, formation of preretinal tractional membrane, and toxic effects of the long-standing hemorrhage, especially at the macula.^[4] Therefore, drainage of a large premacular hemorrhage threatening the visual acuity should be carried out promptly either by laser posterior hyaloidotomy (either Nd: YAG laser or argon laser) or by vitrectomy. Laser drainage of preretinal hemorrhage was first described by Heydenreich in 1973.^[5] Subsequently, several reports have been published regarding the drainage of premacular hemorrhage with various laser systems having a wide range of laser number and energy power used. The range of energies used for Nd: YAG laser hyaloidotomy is 3.6-50 mJ.^[6] The use of Nd: YAG laser has been associated with various complications such as incomplete drainage, rebleeding, epiretinal membrane formation, macular hole, and retinal detachment.^[6] Argon green laser use has been associated with retinal scarring.^[7] These complications are

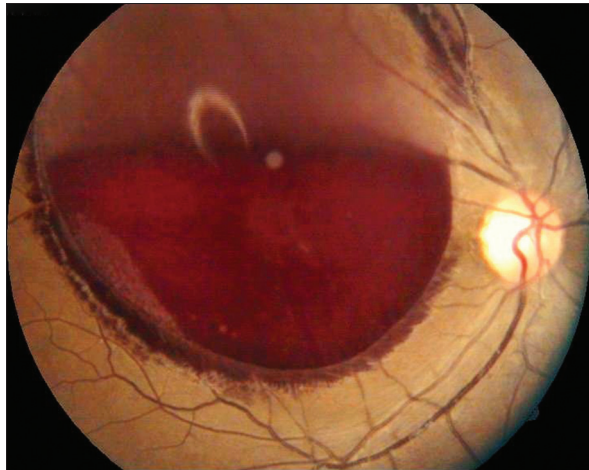


Figure 1: Fundus photo of the right eye showing a large boat-shaped premacular hemorrhage

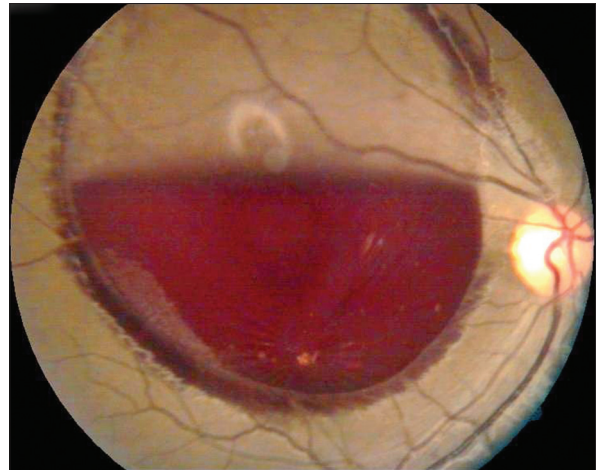


Figure 2: Fundus photo of the right eye showing ILM folds post argon green laser therapy

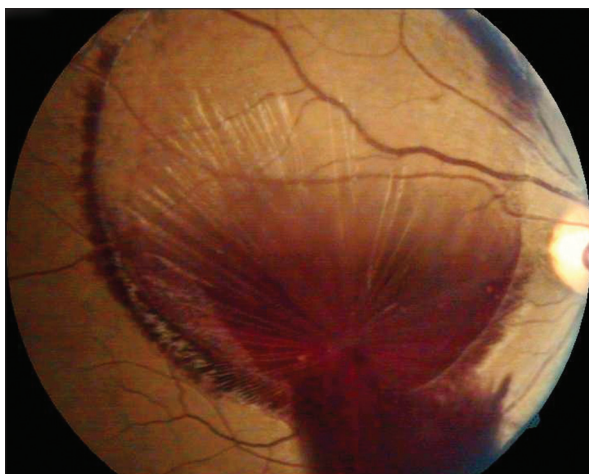


Figure 3: Fundus photo of the right eye showing drainage of the premacular hemorrhage from the defect created by Nd: YAG laser

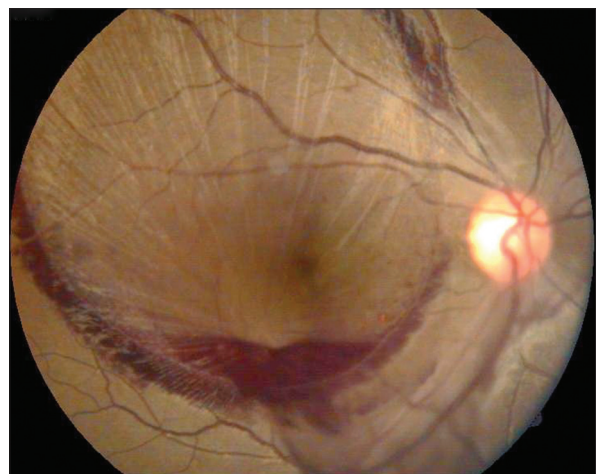


Figure 4: Fundus photo of the right eye showing macular area cleared of hemorrhage

associated with the energy of laser used and the level at which the laser beam is targeted.^[6,7]

There has been only a single published case series comprising of two cases where a combination of argon green laser and Nd: YAG laser has been used to treat premacular hemorrhage.^[8] The Nd: YAG laser energy used in these two cases was 3.9 mJ and 5.1 mJ respectively. In our case report, we have used subthreshold energy levels of Nd: YAG laser (2 mJ) as compared to the original case series as well as the routinely practiced energy levels of 3.6-50 mJ.^[6] This was made possible because of the judicious use of low energy argon green laser to stretch the ILM prior to the application of Nd: YAG laser. The stretching of the ILM made it steady and taut, which enabled even the fewer low energy Nd: YAG laser spots to penetrate it and drain the blood.

The patient benefitted from rapid visual rehabilitation along with lower probability of developing any laser-related complications as the ocular structures were subjected to subthreshold energy levels. Patients, who develop premacular hemorrhage secondary to other retinal pathologies such as PDR, retinal artery macroaneurysms, and venous occlusions, usually require other therapeutic modalities like argon laser photocoagulation to the macula. These can be undertaken only once the premacular hemorrhage is drained. In these cases too, the role of rapid drainage of the hemorrhage by fewer energy levels of laser is crucial to visualize the underlying retina.

In conclusion, we hypothesize that the application of combined argon green laser-Nd: YAG laser at subthreshold energy levels is a justified therapeutic option in cases of premacular hemorrhage. The benefits of the proposed

subthreshold energy level laser include rapid visual rehabilitation, prompt visualization of the underlying retina, and comprehensive access for macular photocoagulation without causing any collateral damage to the retina. We recommend a prospective, randomized long-term study of the various treatment modalities to identify the risks and benefits associated with each of them as well as to formulate a treatment protocol for patients of premacular hemorrhage.

References

1. Gass JD. Stereoscopic Atlas of Retinal Diseases: Diagnosis and Treatment. 3rd ed. St Louis: CV Mosby; 1987. p. 560-4.
2. Raymond LA. Neodymium: YAG laser treatment for hemorrhages under the internal limiting membrane and posterior hyaloid face in the macula. *Ophthalmology* 1995;102:406-11.
3. Sahu DK, Namperumalsamy P, Kim R, Ravindran RD. Argon laser treatment for premacular haemorrhage. *Retina* 1998;18:79-82.
4. Velikay M, Datlinger P, Stolba U, Wedrich A, Binder S, Hausmann N. Retinal detachment with severe proliferative vitreoretinopathy in Terson syndrome. *Ophthalmology* 1994;101:35-7.
5. Heydenreich A. Treatment of preretinal haemorrhages by means of photocoagulation (author's transl). *Klin Monbl Augenheilkd* 1973;163:671-6.
6. Ulbig MW, Mangouritsas G, Rothbacher HH, Hamilton AM, McHugh JD. Long-term results after drainage of premacular subhyaloid hemorrhage into the vitreous with a pulsed Nd: YAG laser. *Arch Ophthalmol* 1998;116:1465-9.
7. Khairallah M, Ladjimi A, Messaoud R, Ben Yahia S, Hmidi K, Jenzeri S. Retinal venous macroaneurysm associated with premacular hemorrhage. *Ophthalmic Surg Lasers* 1999;30:226-8.
8. Emre S, Doganay S, Demirel S, Tasar A. A new technique: Argon green laser-Nd: YAG laser combination for the treatment of premacular haemorrhage. *Acta Ophthalmol* 2010;88:e94-5.

How to cite this article: Sharma A, Sheth JU. Argon green-Nd: YAG dual laser posterior hyaloidotomy: An innovative approach toward treatment of premacular hemorrhage. *Chron Young Sci* 2013;4:170-2.

Source of Support: Lotus Vision Research Fund, **Conflict of Interest:** None declared