

Bilateral ovarian fibromas in a young patient: A rare occurrence

Abstract

Ovarian fibroma accounts for 4% of all ovarian tumors. The mean age of presentation is 48 years. Nearly 10% cases are seen in age less than 30 years. Bilateral fibromas occur in association with nevoid basal cell carcinoma syndrome (gorlin syndrome). We report a case of bilateral fibromas in a 22-year-old female patient with ascites without any evidence of nevoid basal cell carcinoma syndrome.

Key words:

Gorlin syndrome, nevoid basal cell carcinoma syndrome, ovarian fibroma

Introduction

Bilateral ovarian fibromas occur in association with nevoid basal cell carcinoma syndrome. Nevoid basal cell carcinoma syndrome is associated with brain and bone lesions. We present a case of bilateral ovarian fibromas in a 22-year-old female patient with ascites without any evidence of nevoid basal cell carcinoma syndrome along with review of the literature.

Case Report


A 22-year-old nulliparous female patient married for 6 months presented with abdominal pain, irregular menstrual cycles and vaginal spotting. On general physical examination the abdomen was distended and was dull on percussion. Ultrasonography of the abdomen revealed ascitis and bilateral, solid, echogenic adnexal masses. On vaginal examination, bilateral adnexal masses could be palpated in the lateral fornices. A clinical diagnosis of bilateral ovarian tumor was given and hysterectomy with bilateral salpingo-oophorectomy was performed and send for histopathological examination. Grossly, the uterus with bilateral adnexa measured 7 cm × 4.5 cm × 6 cm. Left ovary measured 13 cm × 9 cm × 6 cm and right ovary measured 9 cm × 3 cm × 2 cm. Outer surfaces of both ovaries were pearly white, smooth and nodular [Figure 1]. Cut surface of both ovaries was solid, hard, chalky-white, nodular with

whorled appearance. Microscopic examination of bilateral ovaries revealed interlacing bundles of elongated, thin spindle shaped cells with narrow spindle shaped nuclei parallel to the long axis of the cell. Nuclear palisading, storiform pattern, areas of edema and cyst formation was also seen at places [Figure 2]. Mitotic activity was absent in the spindle cells. Immunohistochemical staining revealed a positive reaction for vimentin and smooth muscle actin and negative immunostaining for keratin and epithelial membrane antigen (EMA). The endometrium was in proliferative phase, myometrium showed normal histology, cervix showed chronic non-specific cervicitis and bilateral fallopian tubes were within the normal limits. On the basis of pathological findings a diagnosis of fibroma, bilateral ovaries were given. A meticulous search was made for any skin lesion or bony lesions but no lesions could be identified.

Discussion

This tumor, which is composed of spindle cells forming variable amounts of collagen, accounts for 4% of all ovarian tumors. Fibroma occurs at all ages, but is most frequent during middle age, with an average age of 48 years.^[1] Fewer than 10% of the cases are encountered under the age of 30 years.

The fibroma is rarely associated with steroid hormone production but may be accompanied by two unusual clinical syndromes, Meigs' syndrome^[2] and the nevoid basal cell

Access this article online	
Website: www.cysonline.org	Quick Response Code 
DOI: 10.4103/2229-5186.129342	

Shailja Puri Wahal, Shobha Mohindroo

Department of Pathology, Indira Gandhi Medical College, Shimla, Himachal Pradesh, India

Address for correspondence:

Dr. Shailja Puri Wahal,
Department of Pathology, Indira Gandhi Medical College,
Shimla - 171 001, Himachal Pradesh, India.
E-mail: drshailjadoe_11@ymail.com

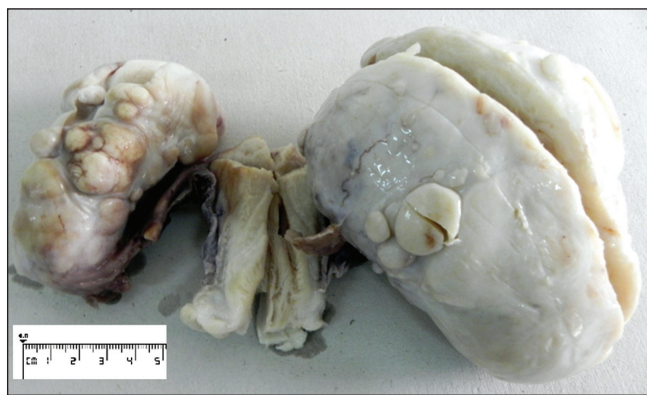


Figure 1: Uterus, cervix with bilateral ovarian masses having pearly white, smooth and nodular outer surface.

carcinoma syndrome (Gorlin syndrome).^[3] Meigs' syndrome complicates about 1% of ovarian fibromas, is defined as ascites and pleural effusion accompanying a fibrous ovarian tumor, usually a fibroma, and disappearing after the removal of the tumor. Ascites alone is present in association with 10-15% of ovarian fibromas larger than 10 cm in diameter.^[4] The most widely accepted explanation of Meigs' syndrome is seepage of fluid from the tumor through its serosal surface into the peritoneal cavity, with subsequent passage into one or both pleural cavities either through lymphatics or through a communication between the abdominal and pleural cavity like the foramen of Bochdalek.^[4] The nevoid basal cell carcinoma syndrome is characterized by one or more of the following findings: Basal cell carcinomas appearing early in life, keratocysts of the jaw, calcification of the dura, mesenteric cysts, and other less common abnormalities^[3] as well as ovarian fibromas, which generally are bilateral, multinodular, and calcified. Unilateral and bilateral ovarian fibromas associated with nevoid basal cell carcinoma syndrome have been reported in young patients by Finch *et al.*^[5] in 2012 and Aram and Moghaddam^[6] in 2009. A case of fibrosarcoma of the ovary in a child with the nevoid basal cell carcinoma syndrome has been reported by Kraemer *et al.*^[7]

Fibromas range in size from microscopic to very large. Sectioning generally reveals hard, flat, chalky-white surfaces that have a whorled appearance. Areas of edema, occasionally with cyst formation, are relatively common. Focal or diffuse calcification and bilaterality are each observed in fewer than 10% of the cases, but these features are characteristic of the fibromas associated with the basal cell nevus syndrome. Microscopic examination reveals intersecting bundles of spindle cells producing collagen; a storiform pattern may be encountered. The presence of bands of hyalinized fibrous tissue is not uncommon. Many tumors show varying degrees of intercellular edema. The cytoplasm of the neoplastic cells of fibromas may contain small quantities of lipid. In rare tumors, the cytoplasm contains small red granules reminiscent of hyaline bodies, probably representing a degenerative phenomenon.

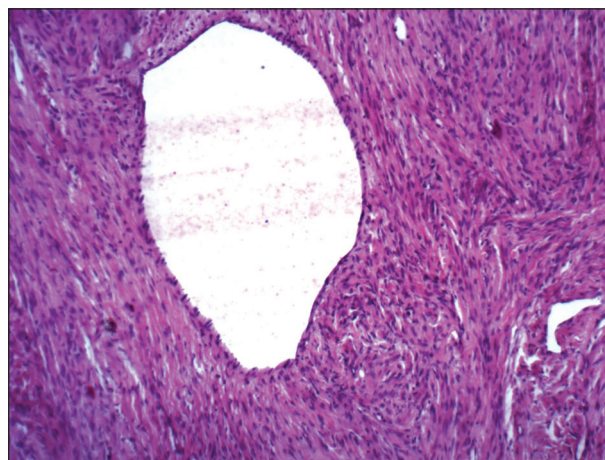


Figure 2: Spindle cells arranged in fascicular and storiform pattern, forming cystic spaces with no atypical mitotic activity (H and E, $\times 40$)

Occasional fibromas may contain a minor component of sex cord elements.

The fibroma must be distinguished from several non-neoplastic ovarian processes, specifically massive edema, fibromatosis, and stromal hyperplasia. The first two disorders usually are unilateral but may be bilateral and are characterized by proliferation of the ovarian stromal cells with marked intercellular edema and the production of abundant dense collagen, respectively. Unlike fibromas, which almost always displace follicles, corpora lutea, and corpora albicantia, massive edema and fibromatosis encompass these structures. Stromal hyperplasia, in contrast to the ovarian fibroma, is bilateral and is characterized by a multinodular or diffuse proliferation of closely packed, small stromal cells with the minimal collagen formation.

Occasional fibromas have varied cellularity and some vascularity, which may cause them to be misinterpreted as sclerosing stromal tumor. The distinct pseudolobulation, lutein cells, and ecstatic vessels, in aggregate, set the sclerosing stromal tumor apart from fibromas that may mimic them to a limited degree. Some fibromas undergo prominent cystic degeneration and may be misconstrued as surface epithelial stromal tumors. However, the cysts (pseudocysts) do not have an epithelial lining.

A subset of ovarian fibromas are intensely cellular and merit the descriptive designation cellular fibroma.^[8] Even when these have relatively brisk mitotic activity, over 4/10 high-power fields, the course is generally clinically uneventful, provided there is no appreciable cytological atypia.^[9] However, rarely, particularly if associated with adhesions or rupture, these tumors can recur and exceptionally even more mundane-appearing fibromas have been reported to implant in the peritoneal surfaces. Most cellular fibromas have alternating cellular and less cellular regions although in some cellularity is diffuse. More or less uniform hypercellularity with significant

cytological atypia and conspicuous mitotic activity merit the diagnosis of fibrosarcoma,^[10] but the distinction between low-grade fibrosarcomas and cellular fibromas is subjective, and it is impossible to provide rigid criteria.

Fibromas should be both grossly and microscopically differentiated from thecoma, Brenner and Krukenberg tumors. Fibromas are solid, firm and uniformly white while thecomas have a yellow color in the cutting surface, an important feature in the differential diagnosis with fibroma. Brenner and Krukenberg tumors were excluded by negative immunoreactivity for keratin and EMA.^[11]

In this case, the age of presentation of ovarian fibroma is less than that reported in literature and is bilateral. Bilateral fibromas are common in individuals with nevoid basal cell carcinoma syndrome. We report this case due to its age of presentation, bilaterality and no association with nevoid basal cell carcinoma syndrome.

References

1. Dockerty MB, Masson JC. Ovarian fibromas: A clinical and pathologic study of two hundred and eighty-three cases. *Am J Obstet Gynecol* 1944;47:741-52.
2. Meigs JV. Fibroma of the ovary with ascites and hydrothorax. Meigs' syndrome. *Am J Obstet Gynecol* 1954;67:962-87.
3. Gorlin RJ. Nevoid basal-cell carcinoma syndrome. *Medicine*. 1987;66:98-113.
4. Samanth KK, Black WC. Benign ovarian stromal tumors associated with free peritoneal fluid. *Am J Obstet Gynecol* 1970;107:538-45.
5. Finch T, Pushpanathan C, Brown K, El-Gohary Y. Gorlin syndrome presenting with a unilateral ovarian fibroma in a 22-year-old woman: A case report. *2012;6:148*.
6. Aram S, Moghaddam NA. Bilateral ovarian fibroma associated with Gorlin syndrome. *Journal of Research in Medical Sciences* 2009;14:57-61.
7. Kraemer BB, Silva EG, Sneige. Fibrosarcoma of the ovary. A new component in the nevoid basal-cell carcinoma syndrome. *Am J Surg Pathol* 1984;8:231-6.
8. Prat J, Scully RE. Cellular fibromas and fibrosarcomas of the ovary: A comparative clinicopathologic analysis of seventeen cases. *Cancer* 1981;47:2663-70.
9. Irving JA, Alkushi A, Young RH, Clement PB. Cellular Fibromas of the ovary: A study of 75 cases including 40 mitotically active tumors emphasizing their distinction from fibrosarcoma. *Am J Surg Pathol* 2006; 30:928-38.
10. Christman JE, Ballon SC. Ovarian fibrosarcoma associated with Maffucci's syndrome. *Gynecol Oncol* 1990;37:290-1.
11. Bjorkholm E, Silfversward. Theca-cell tumors: Clinical features and prognosis. *Acta Radiol Oncol Radiat Phys Biol* 1980;19:241-4.

How to cite this article: Wahal SP, Mohindroo S. Bilateral ovarian fibromas in a young patient: A rare occurrence. *Chron Young Sci* 2014;5:69-71.

Source of Support: Lotus Vision Research Fund, **Conflict of Interest:** None declared