

# Histopathological changes in *Labeo rohita* (Hamilton) fingerlings to various acclimation temperatures

## Abstract

**Background:** Histopathological changes induced by a rise in the acclimation temperature in advanced *Labeo rohita* (Hamilton) fingerlings were studied to understand their adaptive ability to thermal changes. The histopathological changes in relation to the thermal changes have been widely used as bioparameters in the evaluation of fish health. **Materials and Methods:** The six experimental temperatures that the fishes were exposed to were 32, 34, 36, 38, and 40°C for a period of 30 days each. The fishes kept at an ambient temperature of 29.3±1.5°C were used as control. The major organs studied were gills, liver, kidney, and heart. No specific alterations were observed at control, 32, and 34°C. The organs were sampled at the end of 30 days exposure and histopathological changes of different organs were examined. **Result and discussion:** Different organs (gill, liver, kidney and heart) show different histopathological changes in higher temperatures. However, adaptive and degenerative changes were found to occur at the higher temperatures of 36, 38, and 40°C. **Conclusions:** Changes of temperature can be tolerated by the fishes and it brings about adaptive physiological changes to compensate the effects of temperature. **Significance:** The study was helpful; to understand the adaptive mechanisms used by fishes with changes of environmental temperatures.

### Key words:

*Degeneration, histology, Labeo rohita, temperature*

## Introduction

Thermal limits have received much attention because their investigation provides insight into the manner in which climate shapes variation in the ecology, distribution, and evolution of species (Chown and Terblanche<sup>[1]</sup>). Furthermore, upper temperature limits are positively related to optimal performance temperatures (Garland *et al.*<sup>[2]</sup>). Deterioration in the quality of streams over the past 100 years has resulted in the decline or complete loss of many unique and ecologically sensitive endemic fish species. Interactions with exotic organisms, introduction of novel diseases, permanent changes in stream velocity and volume, deterioration of water quality, and alteration of habitat have all contributed to declines in abundance and distribution of fishes (Douglas *et al.*<sup>[3]</sup>). There are numerous secondary responses to thermal stress and these include disturbances

in osmotic and ionic regulation, metabolic processes, growth, reproduction, and behavior. The ultimate response is death. Metabolic and osmoregulatory disturbances during stress are affected by neurohumoral changes. The marked effects of thermal stress on the cardiovascular and respiratory system of freshwater fish have been described in detail by several workers, and the large amount of information on the relationship between temperature and metabolic rates of whole fish or their organs and tissues is summarized in several reviews. There is therefore enormous literature on the physiological responses of freshwater fish to thermal stress and there is a similar amount of information on thermal discharges and their effects on fish.

Histopathological changes have been widely used as biomarkers in the evaluation of the health of fish exposed

**Gadadhar Dash, Prathistha Yonzone, Mukti Chanda<sup>1</sup>, Monjit Paul<sup>1</sup>**

*Department of Fish Pathology, Department of Aquatic Animal Health, Faculty of Fishery Sciences, West Bengal University of Animal and Fishery Sciences, Chakgaria Campus, Kolkata, West Bengal, <sup>1</sup>Asutosh College, Department of Industrial Fish and Fisheries, Kolkata, India*

### Address for correspondence:

Prof. Mukti Chanda  
Sai Apartment, 65 (33), A Road, Anandapuri  
Barrackpore, Kolkata – 700 122,  
E-mail: muktichanda@gmail.com

Access this article online	
<b>Website:</b> <a href="http://www.cyonline.org">http://www.cyonline.org</a>	<b>Quick Response Code</b> 
<b>DOI:</b> 10.4103/2229-5186.79347	

to contaminants, both in the laboratory (Thophon *et al.*<sup>[4]</sup>) and field studies (Teh *et al.*<sup>[5]</sup>). One of the great advantages of using histopathological biomarkers in environmental monitoring is that this category of biomarkers allows examining specific target organs, including gills, kidney, and liver, which are responsible for vital functions, such as respiration, excretion, and the accumulation and biotransformation of xenobiotics in the fish (Gernhofer *et al.*<sup>[6]</sup>). Heat injury is observed in cells at temperatures only slightly higher than the normal range. In general, cells respond to sublethal thermal stress with alterations in cellular physiology that confer resistance to normally lethal temperatures. There appear to be two states of this acquired thermo-tolerance. One ( $\alpha$  state) is unstable and independent of protein synthesis, whereas the other ( $\beta$  state) is longer lived and requires protein synthesis (Laszlo<sup>[7]</sup>). Responses to thermal stress by expression of HSPs (heat shock protein) in fish are well documented with the HSP70 family (Hofmann *et al.*<sup>[8]</sup> and Muller *et al.*<sup>[9]</sup>).

## Materials and Methods

### Test fish and temperature acclimatization

Apparently, healthy advanced fingerlings of rohu (*Labeo rohita*) measuring  $17.58 \pm 0.44$  cm (standard error) and weighing  $48.58 \pm 5.06$  g were obtained each month from the local bheries (these are traditional bigger water bodies either saline, medium saline, or fresh water located in the eastern fringe of Kolkata, West Bengal, which is locally called Bheries. Here, traditional fish/shrimp cultures are practiced. These are same as like that of Pokali prawn fields of Kerala, Gazni of North Karnataka, etc.) and the college hatchery. Fishes were brought to the laboratory and acclimatized for one week in 500 l FRP (Fiber Reinforced Plastic) tanks with aeration facilities prior to experiment. At the end of one week, the fishes were divided into three groups of five fingerlings each and stocked in 50 l glass aquaria. Pelleted feed was given at 4% of the body weight throughout the experiment. Uneaten feed and fecal matter were siphoned out on alternate days from the experimental tanks. With the help of a Digital Temperature Controller (Digital thermostat), the temperature was gradually increased from the normal water temperature to the experimental temperature at the rate of  $1^\circ\text{C}$  per day. The six experimental temperatures that the fishes were exposed to were 32, 34, 36, 38, and  $40^\circ\text{C}$  for duration of 30 days each (temperature of the laboratory was  $30 \pm 0.5^\circ\text{C}$ ). The fishes kept at an ambient temperature of  $29.3 \pm 1.5^\circ\text{C}$  were used as control.

### Tissue sampling and processing

The organs were sampled at the end of the 30 days' exposure period at each temperature. Tissue samples of gills, kidney, liver, and heart were removed, fixed in 10% buffered formalin, and routinely processed for paraffin embedding. Sections were cut at  $5 \mu\text{m}$  and the prepared slides were stained with hematoxylin and eosin and observed under the

trinocular phase-contrast research microscope with in-built digital camera and attached monitor (Motic: Model BA 400).

### Histopathological observations at different temperatures

No specific alterations were found in the histology of the organs of the fishes exposed to control ( $29.3 \pm 1.5$ ), 32, and  $34^\circ\text{C}$ . The changes observed at the higher temperatures are documented in the given figures.

## Result and Discussion

### Gill

Gill of *L. rohita* at  $36^\circ\text{C}$  showed primary lamellar hyperplasia (green arrow) and swollen bases of secondary lamellae (blue arrow) (H and E,  $\times 100$ ) [Figure 1]. Gill of *L. rohita* at  $38^\circ\text{C}$  showed thickened primary lamella (blue arrow) and shortened and walled off secondary lamellae (yellow arrow) (H and E,  $\times 100$ ) [Figure 2]. Gill of *L. rohita* at  $38^\circ\text{C}$  showed exaggerated thickening of primary lamella (green arrow) (H and E,  $\times 100$ ) [Figure 3]. Gill of *L. rohita* at  $40^\circ\text{C}$  showed primary lamellar degeneration (red arrow) and clubbing of secondary lamellae (yellow arrow) (H and E,  $\times 100$ ) [Figure 4]. Gill of *L. rohita* at  $40^\circ\text{C}$  showed lamellar fusion (red arrow) and clubbing of the secondary lamellae (yellow arrow) (H and E,  $\times 100$ ) [Figure 5].

The gill lamellae are the primary site of gas exchange, making up most of the respiratory surface area of fish gills. The fishes maintained at higher temperatures in the present study were subjected to functional as well as general hypoxia. Recently, there have been a number of studies showing that gill morphology in many teleost fishes is plastic (Brauner *et al.*<sup>[10]</sup> and Ong *et al.*<sup>[11]</sup>) and can be greatly altered within hours today during exposure to hypoxia (Sollid and Nilsson<sup>[12]</sup>). There is a well-documented respiratory osmoregulatory compromise at the gills, such that effective gill area and diffusion distance are adjusted to provide the permeability required for gas exchange, while minimizing the permeability for diffusive ion losses and osmotic water gain (Gonzalez and McDonald<sup>[13]</sup>).

### Liver

Liver of *L. rohita* at  $36^\circ\text{C}$  showed disarrangement of hepatic cells (green arrow) and vacuolar degeneration (yellow arrow) (H and E,  $\times 400$ ) [Figure 6]. Liver of *L. rohita* at  $36^\circ\text{C}$  showed canaliculi formation (arrow) (H and E,  $\times 400$ ) [Figure 7]. Liver of *L. rohita* at  $38^\circ\text{C}$  showed prominent vacuolation (yellow arrow) (H and E,  $\times 100$ ) [Figure 8]. Liver of *L. rohita* at  $38^\circ\text{C}$  showed prominent vacuolation (yellow arrow) and nodule formation (blue arrow) (H and E,  $\times 100$ ) [Figure 9]. Liver of *L. rohita* at  $40^\circ\text{C}$  showed increased melanin production (yellow arrow) and eosinophilic deposition (blue arrow) in the vacuole (H and E,  $\times 400$ ) [Figure 10]. Liver of *L. rohita* at  $40^\circ\text{C}$  showed increased melanin production (green arrow) and canaliculi formation (purple arrow) (H and E,  $\times 400$ ) [Figure 11].

The most common alterations in the liver of the fishes in the present study at higher acclimation temperatures were cloudy swelling and necrosis of the hepatic cells leading to prominent vacuolar degeneration of the hepatocytes. The present results are in agreement with those observed by many authors who have studied the effects of different pollutants on fish liver (Fanta *et al.*<sup>[14]</sup> and Olojo *et al.*<sup>[15]</sup>). The vacuolization of hepatocytes might indicate an imbalance between the rate of synthesis of substances in the parenchymal cells and the rate of their release into the circulation system (Gingerich<sup>[16]</sup>). Most poikilotherms respond to thermal changes by adapting the physical properties of their membranes to the new situation to preserve the functional and structural integrity of these structures, a phenomenon that Sinensky<sup>[17]</sup> termed "homeoviscous adaptation." The homeoviscous efficacy, the extent to which the cells compensate for temperature changes, varies among the tissues and membranes (Cossins and Prosser<sup>[18]</sup> and Lee and Cossins<sup>[19]</sup>). Adjustment of the physicochemical properties of the membranes to the temperature is expected to be rapid and reversible to ensure proper functioning under fluctuating thermal conditions in fish. Wodtke and Cossins<sup>[20]</sup> have shown that the fluidity of the mitochondria in fish liver follows changes in the environmental temperature, which may have been the cause of the alterations observed in the hepatocytes. Haschemeyer and Mathews<sup>[21]</sup> conducted experiments to test the ability of the liver protein synthetic system to maintain coordination during acute exposure to high temperatures and found that at high temperatures, protein synthetic reactions showed a loss of coordination, with elongation rate increasing normally, while amino acid incorporation declined.

### Kidney

Kidney of *L. rohita* at 36°C showed mild vacuolar degeneration (green arrow) (H and E, ×100) [Figure 12]. Kidney of *L. rohita* at 36°C showed dark granular or pigment deposits (arrows) (H and E, ×100) [Figure 13]. Kidney of *L. rohita* at 38°C showed degeneration and complete loss of cellular organization (arrows) (H and E, ×100) [Figure 14]. Higher magnification showing cloudy appearance of the cells (H and E, ×400) [Figure 15]. Kidney of *L. rohita* at 40°C showed massive vacuolar degeneration of the renal tissue (yellow arrows) (H and E, ×100) [Figure 16]. Higher magnification showing the formation of an infarct (purple arrow) (H and E, ×400) [Figure 17].

In the present study, kidney of the fish often showed vacuolar degeneration (cloudy swelling) in tubular cells, lysis of the renal tubules, loss of tubular structure, and organization and massive vacuolar degeneration. The necrosis of the renal tubules affects the metabolic activities and promotes metabolic abnormalities in fish (Yokote<sup>[22]</sup>). The present results are in agreement with those observed in *Cyprinus carpio* exposed to sewage (Kakuta and Murachi<sup>[23]</sup>), *Prochilodus lineatus* exposed to trichlorfon (Veiga *et al.*<sup>[24]</sup>), and *Lates calcarifer* exposed to cadmium

(Thophon *et al.*<sup>[4]</sup>). Also, Velmurugan *et al.*<sup>[25]</sup> observed necrosis of tubular epithelium, hypertrophied epithelial cells of renal tubules, narrowing of the tubular lumen, expansion of space inside the Bowman's capsules, and contraction of the glomerulus in the kidney of *Cirrhinus mrigala* exposed to fenvalerate. However, Camargo and Martinez<sup>[26]</sup> found cloudy swelling degeneration in the epithelium of renal tubules in the kidney of *P. lineatus* caged in Cambe stream, Brazil, polluted by industrial, domestic, and agricultural wastes.

### Heart

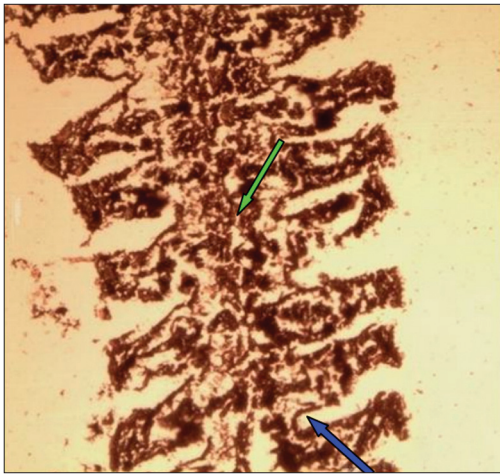
Heart of *L. rohita* at 36°C showed mild degeneration of myofibrillar layer (arrows) (H and E, ×1000) [Figure 18]. Heart of *L. rohita* at 36°C showed massive vacuolar degeneration (yellow arrow) and extravasated erythrocytes (blue arrow) (H and E, ×1000) [Figure 19]. Heart of *L. rohita* at 38°C showed fragmentation of myocardial muscle fiber (yellow arrows) (H and E, ×100) [Figure 20]. Heart of *L. rohita* at 38°C showed infiltration of edematous fluid into the vacuolar space (arrows) (H and E, ×100) [Figure 21]. Heart of *L. rohita* at 40°C showed massive degeneration of the myotomic tissue (yellow arrows) (H and E, ×100) [Figure 22]. Heart of *L. rohita* at 40°C showed canaliculi formation (blue arrow) (H and E, ×100) [Figure 23].

The major changes observed in the heart of the fishes exposed to stressfully high temperatures were massive degeneration of the myotomic cells with the formation of degenerative vacuoles and canaliculus containing dark and necrotized cellular aggregates. Similar changes were observed by Das and Mukherjee<sup>[27]</sup> in the effect of hexachlorocyclohexane on *L. rohita* and as an effect of selected metal toxicity (Fatma<sup>[28]</sup>). Myocardial fragmentation observed may have occurred as a result of heat injury. The degeneration and necrosis could be attributed to the increased catecholamine release, as previously reported by Lennard and Huddart,<sup>[29]</sup> which in the present study may have been as a response to thermal stress. At 38°C, light yellow edematous fluid was observed in the vacuolar spaces. Possible causes may include changes in hydrostatic or osmotic pressure (cardiac failure, vascular obstructions, hypoproteinemia) and increases in vascular permeability that accompanies inflammation as temperature is known to have effects on cardiac function and osmoregulation. The occurrence of dark and necrotized cellular aggregates at 40°C can be attributed to increased melanin secretion by the tissues in response to thermal stress.

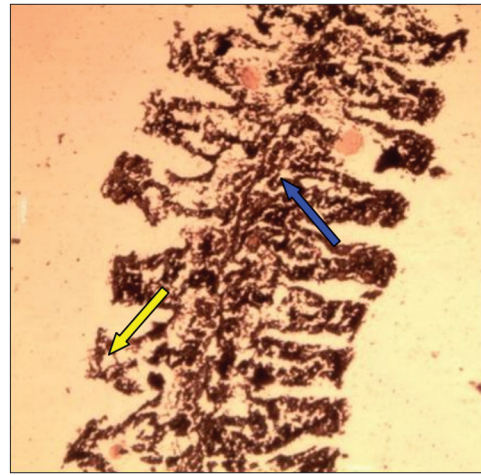
### Conclusion

The present study brings about the conclusion that increased water temperatures create stressful environments for the fishes. Temperature rise up to a certain point are tolerated by fishes through thermoregulation, whereby they bring about adaptive physiological changes in order

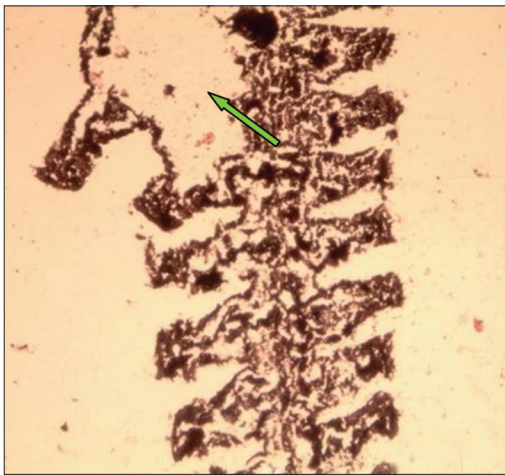




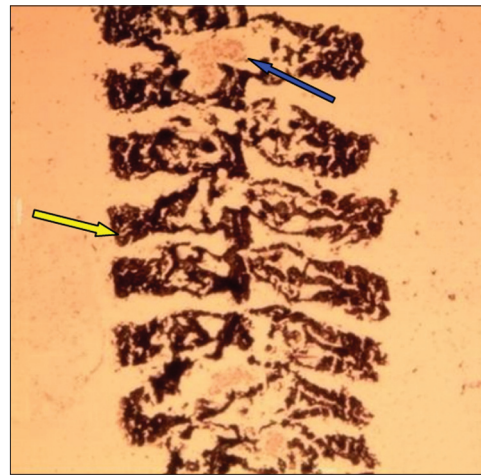
**Figure 1:** Gill of *Labeo rohita* at 36°C showing primary lamellar hyperplasia (green arrow) and swollen bases of secondary lamellae (blue arrow) (H and E, ×100)



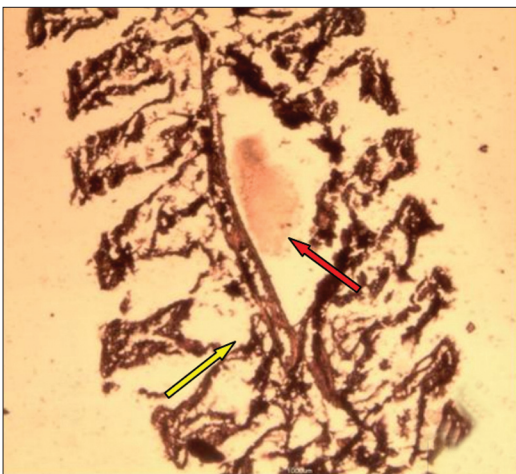**Figure 2:** Gill of *Labeo rohita* at 38°C showing thickened primary lamella (blue arrow) and shortened and walled off secondary lamellae (yellow arrow) (H and E, ×100)



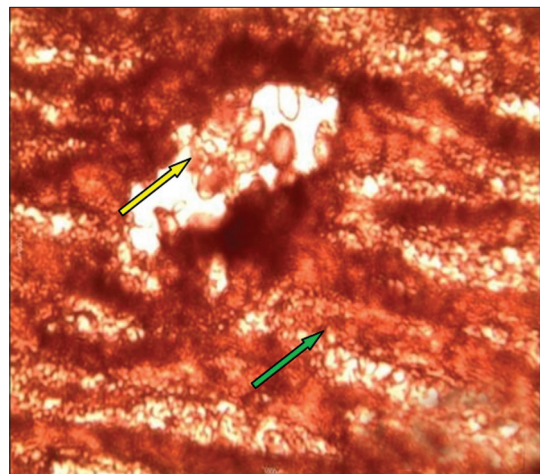
**Figure 3:** Gill of *Labeo rohita* at 38°C showing exaggerated thickening of primary lamella (green arrow) (H and E, ×100)



**Figure 4:** Gill of *Labeo rohita* at 40°C showing primary lamellar degeneration (red arrow) and clubbing of secondary lamellae (yellow arrow) (H and E, ×100)

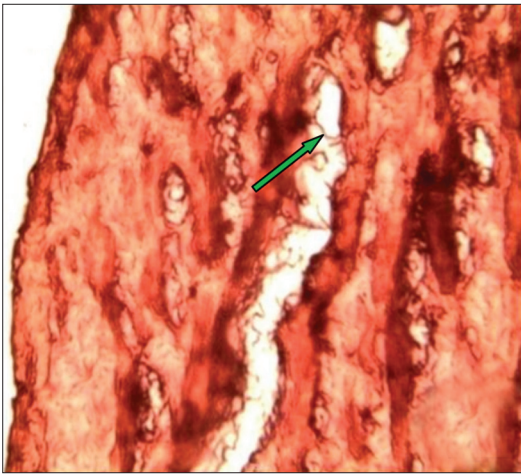


**Figure 5:** Gill of *Labeo rohita* at 40°C showing lamellar fusion (red arrow) and clubbing of the secondary lamellae (yellow arrow) (H and E, ×100)

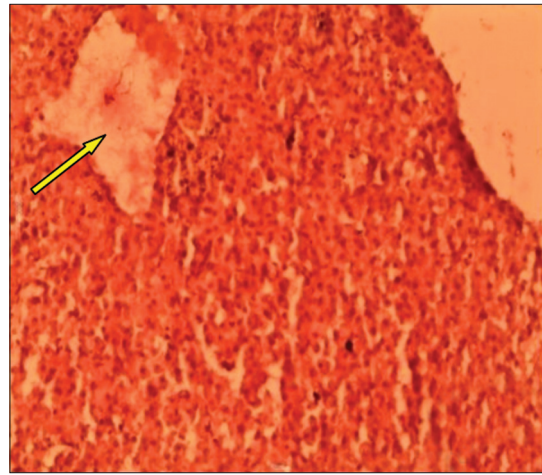


**Figure 6:** Liver of *Labeo rohita* at 36°C showing disarrangement of hepatic cells (green arrow) and vacuolar degeneration (yellow arrow) (H and E, ×400)

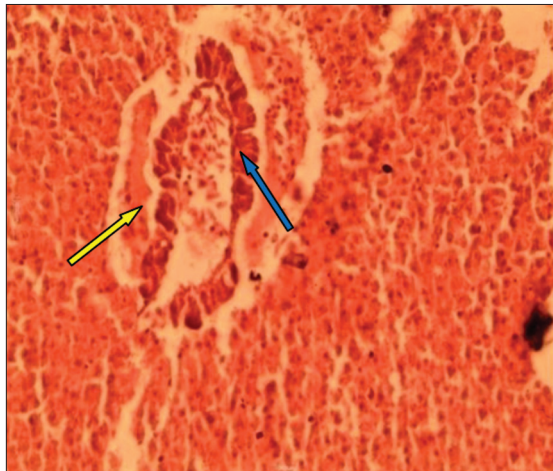




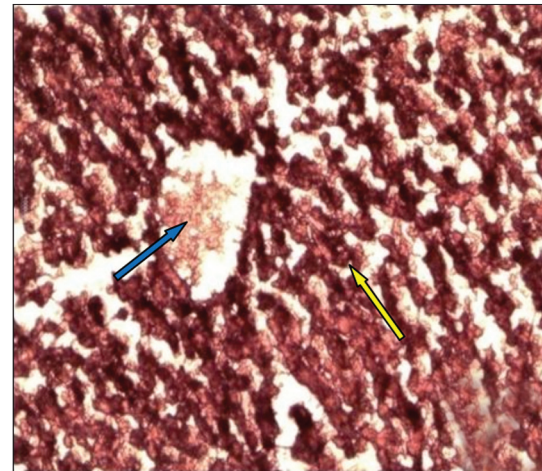
**Figure 7:** Liver of *Labeo rohita* at 36°C showing canalicular formation (arrow) (H and E,  $\times 400$ )



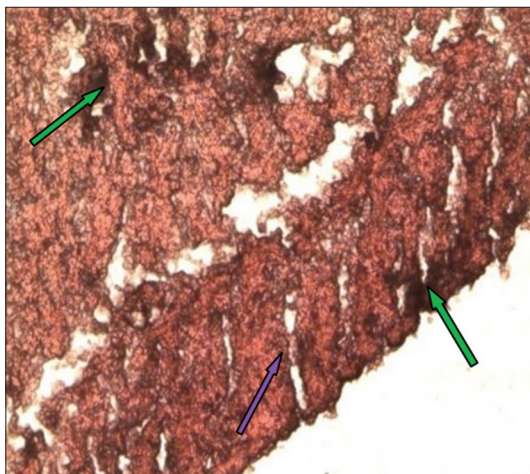
**Figure 8:** Liver of *Labeo rohita* at 38°C showing prominent vacuolation (yellow arrow) (H and E,  $\times 100$ )



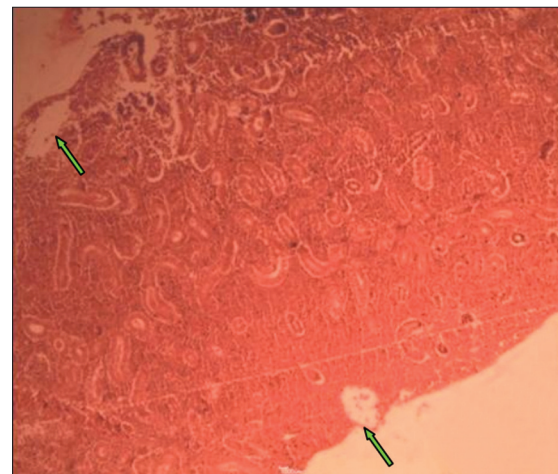
**Figure 9:** Liver of *Labeo rohita* at 38°C showing prominent vacuolation (yellow arrow) and nodule formation (blue arrow) (H and E,  $\times 100$ )



**Figure 10:** Liver of *Labeo rohita* at 40°C showing increased melanin production (yellow arrow) and eosinophilic deposition (blue arrow) in the vacuole (H and E,  $\times 400$ )

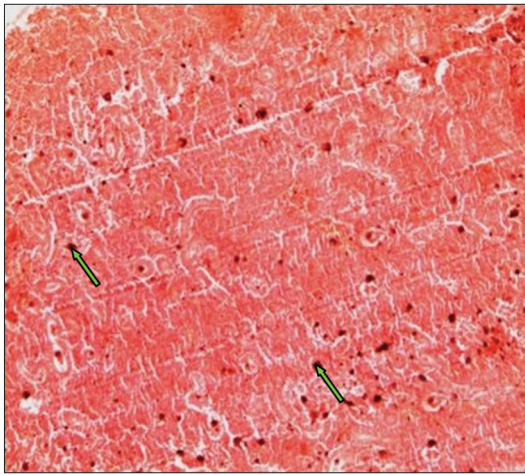


**Figure 11:** Liver of *Labeo rohita* at 40°C showing increased melanin production (green arrow) and canalicular formation (purple arrow) (H and E,  $\times 400$ )

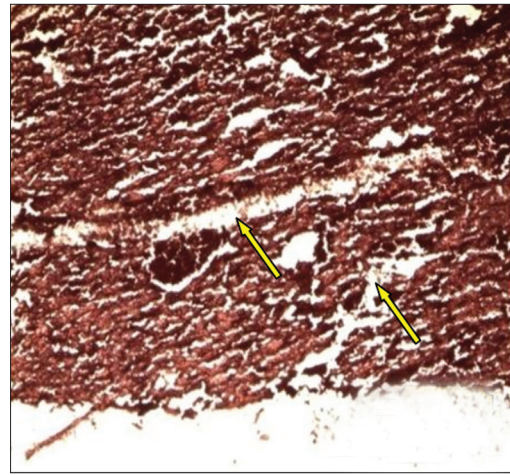


**Figure 12:** Kidney of *Labeo rohita* at 36°C showing mild vacuolar degeneration (green arrow) (H and E,  $\times 100$ )

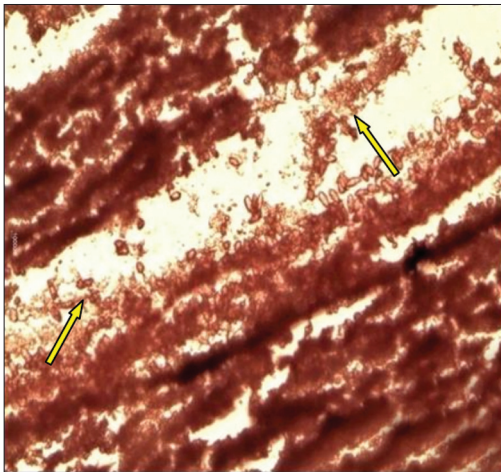




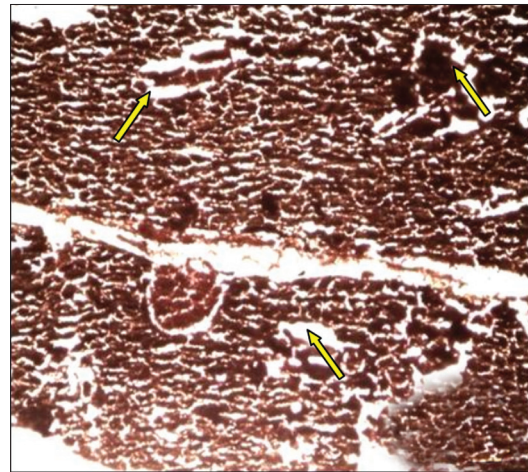
**Figure 13:** Kidney of *Labeo rohita* at 36°C showing dark granular or pigment deposits (arrows) (H and E,  $\times 100$ )



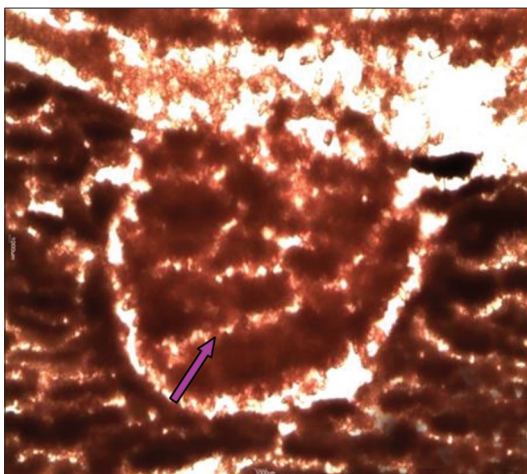
**Figure 14:** Kidney of *Labeo rohita* at 38°C showing degeneration and complete loss of cellular organization (arrows) (H and E,  $\times 100$ )



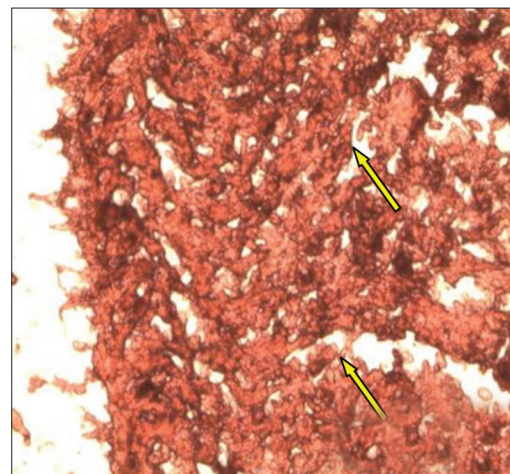
**Figure 15:** Higher magnification of the Figure 15 showing cloudy appearance of the cells (H and E,  $\times 400$ )



**Figure 16:** Kidney of *Labeo rohita* at 40°C showing massive vacuolar degeneration of the renal tissue (yellow arrows) (H and E,  $\times 100$ )

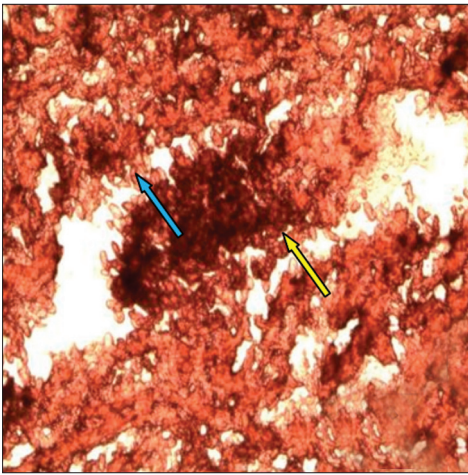


**Figure 17:** Kidney of *Labeo rohita* at 40°C showing massive vacuolar degeneration of the renal tissue (yellow arrows) (H and E,  $\times 100$ )

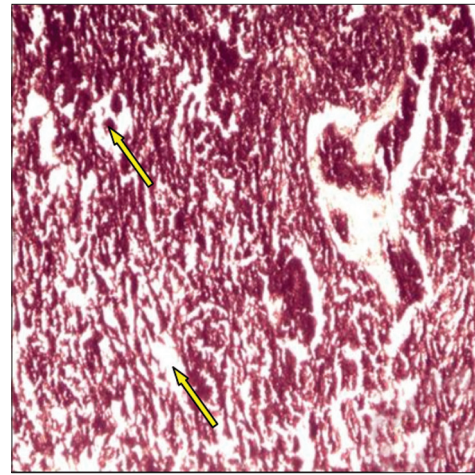


**Figure 18:** Heart of *Labeo rohita* at 36°C showing mild degeneration of myofibrillar layer (arrows) (H and E,  $\times 1000$ )

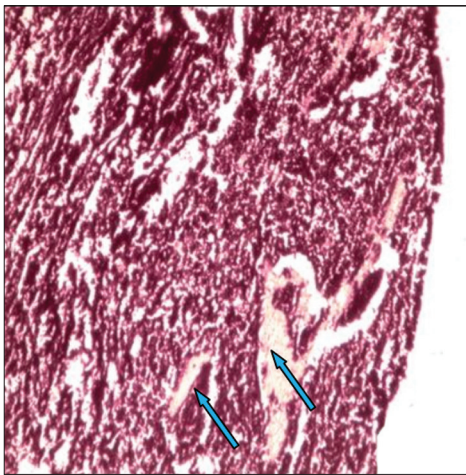




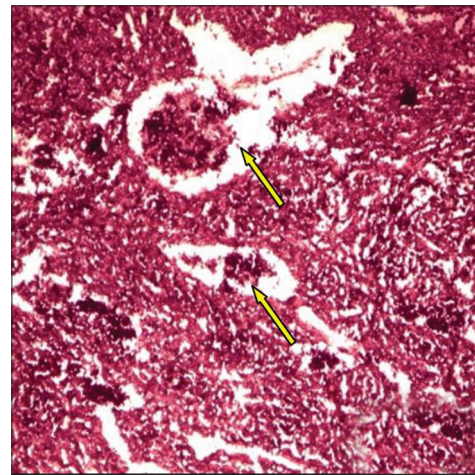
**Figure 19:** Heart of *Labeo rohita* at 36°C showing massive vacuolar degeneration (yellow arrow) and extravasated erythrocytes (blue arrow) (H and E,  $\times 1000$ )



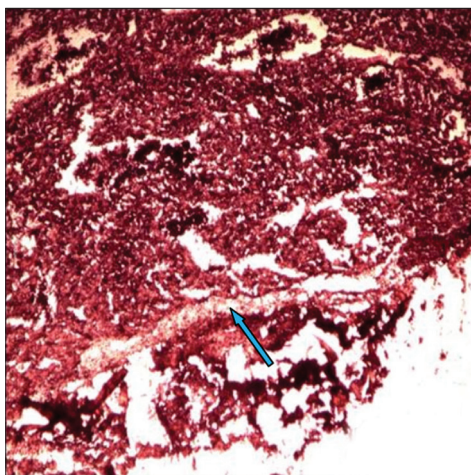
**Figure 20:** Heart of *Labeo rohita* at 38°C showing fragmentation of myocardial muscle fiber (yellow arrows) (H and E,  $\times 100$ )



**Figure 21:** Heart of *Labeo rohita* at 38°C showing infiltration of edematous fluid into the vacuolar space (arrows) (H and E,  $\times 100$ )



**Figure 22:** Heart of *Labeo rohita* at 40°C showing massive degeneration of the myotic tissue (yellow arrows) (H and E,  $\times 100$ )



**Figure 23:** Heart of *Labeo rohita* at 40°C showing canaliculi formation (blue arrow) (H and E,  $\times 100$ )

to compensate, partially or completely, for the effects of temperature on the rate of body functions, that is, they tend to maintain metabolism, locomotion, and cardiac function relatively independent of temperature changes. However, although they are known to be highly adaptive, extreme temperature stress can have lethal effects on its internal physiology and its inability to adapt leads to metabolic depression, as observed at 38°C, or mortality, as observed at 40°C. Fishes in the natural environment are faced with such thermal challenges due to thermal pollution of rivers and lakes that cause abrupt rise in water temperature and subject the fishes to acute thermal stress. Rising air temperatures due to global warming are having an impact on the water temperature which are known to be causing population shifts and habitat loss in the natural water ecosystem. Seasonal and diurnal fluctuations in temperature also subject the fishes to short-term thermal challenges.



### Significance

The present study was helpful in understanding the adaptive mechanism used by the fishes in such environments and also that Indian major carps like *L. rohita* should not be cultured at temperatures above 32°C as after a certain point, increased temperature leads to declined growth which will reduce the productivity. Knowledge of the interactions of temperature with other variables can be useful to fish culturists in determining the optimal frequency of feeding, amount of feed, and composition of the diet. In addition, such knowledge is necessary to determine the economic feasibility of controlling temperatures in tank or raceways high-density culture systems. Since it is impractical to heat or cool large volumes of water in open ponds or culture systems, species selection should be based on anticipated water temperature, and the optimum thermal range for the species being cultured should be known as it varies interspecifically.

The histopathological alterations observed were in response to disturbed physiology of the fishes at warmer temperatures, functional hypoxia, and heat injury. The gills being the respiratory and osmoregulatory organ of the fishes showed adaptive changes at 34 and 36°C in order to obtain more oxygen from the water but at higher temperatures of 38 and 40°C, degenerative changes were observed. In all other major organs like kidney, liver, and heart, degeneration and disarrangement of cells were evident. Vacuolization was found to occur in all the tissues due to an imbalance between the rate of synthesis of substances in the parenchymal cells and the rate of their release into the circulation system. There was complete loss of cellular structure and organization at the extremely stressful temperatures. The performance of a fish is thus guided by the ambient temperature of its surrounding water and it responds to a rise in the temperature by means of physiological adaptations which may be revealed in its blood physiology, cellular character, and its behavior.

### References

- Chown SL, Terblanche JS. Physiological diversity in insects: Ecological and evolutionary contexts. *Adv Insect Physiol* 2007;33:50-152.
- Garland T, Huey RB, Bennett AF. Phylogeny and coadaptation of thermal physiology in lizards: A reanalysis. *Evolution* 1991;45:1969-75.
- Douglas ME, Marsh PC, Minckley WL. Indigenous fishes of western North America and the hypothesis of competitive displacement: *Medafulgida* (Cyprinidae) as a Case Study. *Copeia* 1994;1:9-19.
- Thophon S, Kruatrachue M, Upathan ES, Pokethititoyok P, Sahaphong S, Jarikhuan S. Histopathological alterations of white seabass, *Latescalcarifer* in acute and subchronic cadmium exposure. *Env Pollu* 2003;121:307-20.
- Teh SJ, Adams SM, Hinton DE. Histopathological biomarkers in feral freshwater fish populations exposed to different types of contaminant stress. *Aquat Toxicol* 1997;37:51-70.
- Gernhofer M, Pawet M, Schramm M, Muller E, Triebkorn R. Ultrastructural biomarkers as tools to characterize the health status of fish in contaminated streams. *J Aquat Ecosys* 2001;8:241-60.
- Laszlo A. Evidence for two states of thermotolerance in mammalian cells. *Int JHypertherm* 1988;4:513-26.
- Hofmann GE, Lund SG, Place SP, Whitmer AC. The heat shock response is found in New Zealand but not Antarctic notothenioid fishes. *J Exp Mar Biol Ecol* 2005;316:79-89.
- Muller WE, Belikov SI, Kaluzhnaya OV, Perovic OS, Fattorusso E, Ushijima H, et al. Cold stress defence in the fresh water sponge *Lubomirskiabaicalensis* *Febs J* 2007;274:23-36.
- Brauner CJ, Matey V, Wilson JM, Bernier NJ, Val AL. Transition in organ function during the evolution of air-breathing; insights from *Arapaima gigas*, an obligate air-breathing teleost from the Amazon. *J Exp Biol* 2004;207:1433-8.
- Ong KJ, Stevens ED, Wright PA. Gill morphology of the mangrove killifish (*Kryptolebias marmoratus*) is plastic and changes in response to terrestrial air exposure. *J Exp Biol* 2007;210:1109-15.
- Sollid J, Nilsson GE. Plasticity of respiratory structures: Adaptive remodeling of fish gills induced by ambient oxygen and temperature. *Respir Physiol Neurobiol* 2006;154:241-51.
- Gonzalez RJ, McDonald DG. The relationship between oxygen consumption and ion loss in a freshwater fish. *J Exp Biol* 1992;163:317-32.
- Fanta E, Rios FS, Romao S, Vianna AC, Freiberger S. Histopathology of the fish *Corydoras paleatus* contaminated with sublethal levels of organophosphorus in water and food. *Ecotoxicol Environ Saf* 2003;54:119-30.
- Olojo EA, Olurin GM, Oluwemimo A. Histopathology of the gill and liver tissues of the African catfish *Clarias gariepinus* exposed to lead. *Afr J Biotechnol* 2005;4:117-22.
- Gingerich WH. Hepatic Toxicology of Fishes. Aquatic Toxicology. In: Weber LJ, editor. New York: Raven Press; 1982.p. 55-105.
- Sinensky M. Homeoviscous adaptation-A homeostatic process that regulates the viscosity of membrane lipids in *Escherichia coli*. *Proc Natl Acad Sci USA* 1974;71:522-5.
- Cossins AR, Prosser CL. Variable homeoviscous responses of different brain membranes of thermally acclimated goldfish. *Biochim Biophys Acta* 1982;687:303-9.
- Lee JA, Cossins AR. Temperature adaptation of biological membranes: Differential homeoviscous responses in brush-border and basolateral membranes of carp intestinal mucosa. *Biochim Biophys Acta* 1990;1026:195-203.
- Wodtke E, Cossins AR. Molecular and structural composition of phospholipid membranes in fish. *Biochem Biophys Acta* 1991;1069:343-50.
- Haschemeyer AE, Mathews RW. Effects of temperature extremes on protein synthesis in liver of toadfish, *Opsanus tau*, *in vivo*. *Biol Bull* 1982;16:218-27.
- Yokote M. Digestive system. An atlas of fish histology-normal and pathological features In: Hibiya T, editor. Tokyo: Kodansha Ltd; 1982.p. 74-93.
- Kakuta I, Murachi S. Physiological response of carp, *Cyprinus carpio*, exposed to raw sewage containing fish processing wastewater. *Environ Toxicol Water Qual* 1997;12:1-9.
- Veiga M, Rodrigues E, Pacheco F, Ranzani-Paiva M. Histopathological changes in the kidney tissue of *Prochilodus lineatus*, 1836 (Characiformes, Prochilodontidae) induced by sublethal concentration of Trichlorfon exposure. *Braz Arch Biol Technol* 2002;45:171-5.
- Velmurugan B, Selvanayagam M, Cengiz E, Unlu E. The effects of fenvalerate on different tissues of freshwater fish *Cirrhinus mrigala*. *J Environ Sci Health B* 2007;42:157-63.
- Camargo MM, Martinez CB. Histopathology of gills, kidney and liver of a Neotropical fish caged in an urban stream. *Neotrop Ichthyol* 2007;5:327-36.
- Das BK, Mukherjee SC. Sublethal Effect of Quinalphos on Selected Blood Parameters of *Labeo rohita* (Ham.) Fingerlings. *Asian Fish Sci* 2000;13:225-33.
- Fatma AS. Bioaccumulation of Selected Metals and Histopathological Alterations in Tissues of *Oreochromis niloticus* and *Lates niloticus* from Lake Nasser. *Egypt Glob Vet* 2008;2:205-18.
- Lennard R, Huddart H. The effects of hypoxic stress on the fine structure of the flounder heart (*Platichthys flesus*). *Comp Biochem Physiol* 1992;101:723-32.

**How to cite this article:** Dash G, Yonzone P, Chanda M, Paul M. Histopathological changes in *Labeo rohita* (Hamilton) fingerlings to various acclimation temperatures. *Chron Young Sci* 2011;2:29-36.

**Source of Support:** Nil, **Conflict of Interest:** None declared